

## CASE REPORT

# A Multidisciplinary Approach for Rehabilitation following Ocular Trauma

<sup>1</sup>Milap H Karia, <sup>2</sup>Hiral M Karia

## ABSTRACT

An eye for an eye is what the old saying goes. The eye plays a vital role as one of the six senses. From vision to expression, it has its varied functions. Loss of this organ severely damages not only the function of vision but also self-confidence. A case report is presented wherein a simple technique is used to provide the subject with an eye prosthesis as rapidly as possible. Also, digital reproduction of the iris is made, instead of painting the iris using acrylic or oil painting.

**Keywords:** Addition silicone impression material, Conformer, Enucleation, Ocular prosthesis.

**How to cite this article:** Karia MH, Karia HM. A Multidisciplinary Approach for Rehabilitation following Ocular Trauma. *Int J Prev Clin Dent Res* 2017;4(4):342-344.

**Source of support:** Nil

**Conflict of interest:** None

## INTRODUCTION

The loss or absence of an eye may be due to congenital defect, irreparable trauma, tumor, painful blind eye, sympathetic ophthalmia, or the need for histological confirmation of a suspected diagnosis.<sup>1</sup> Surgical procedures in the removal of an eye can be broadly classified as evisceration (where the contents of the globe are removed leaving the sclera intact), enucleation (most common, where the entire eyeball is removed after severing the muscles and the optic nerve), and exenteration (where the entire contents of the orbit including the eyelids and the surrounding tissues are removed).<sup>2</sup> In such cases, artificial eye prosthesis replaces the natural eye. The art and techniques of artificial eye fabrication date back to remote times. Artificial eye has been in presence since the times of the Egyptians before 3000 BC. It was only after the 16th century that artificial eye was made to fit the socket. Ambroise Parre made use of both glass and

porcelain eye. Glass was eventually replaced by acrylic during and after the two World Wars.<sup>3-6</sup>

An ocular prosthesis is a maxillofacial prosthesis that artificially replaces an eye missing as a result of trauma, surgery, or congenital absence. The prosthesis does not replace missing eyelids or adjacent skin, mucosa, or muscle.<sup>5</sup> In this case report, an ocular prosthesis was fabricated with digital duplication of iris of the patient.

## CASE REPORT

A 60-year-old male subject reported to the Department of Prosthodontics, Pacific Dental College & Hospital, Udaipur, Rajasthan, India, with the chief complaint of misplaced ocular prosthesis. Past history revealed loss of eye due to trauma and subsequent evisceration. Examination of the tissue bed revealed intact muscle bed with residual movements present (Fig. 1).

Since subject stated an urgency to get rehabilitated, a discourse from the usual procedure of fabrication of customized ocular prosthesis was chosen. Here, impression of the tissue bed was made diimcarectly with the syringe tip of additional silicone elastomer impression material (Aquasil, Dentsply) (Fig. 2). The tip was disengaged from the loading gun and invested in irreversible hydrocolloid and dental plaster to support the impression (Fig. 3). Type III dental stone was poured in the impression and three-part cast obtained. Modeling wax was poured in the obtained mold to obtain the scleral wax pattern (Fig. 4). This wax pattern was placed in the defect

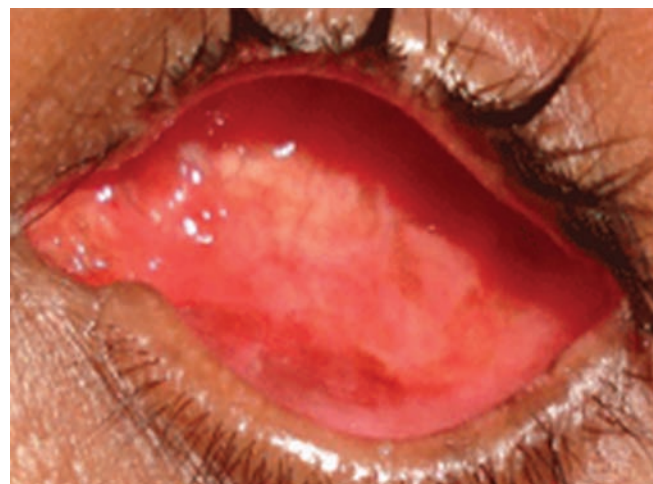


Fig. 1: Preoperative photo of ocular defect

<sup>1,2</sup>Senior Lecturer

<sup>1,2</sup>Department of Prosthodontics, Darshan Dental College & Hospital, Udaipur, Rajasthan, India

**Corresponding Author:** Milap H Karia, Senior Lecturer Department of Prosthodontics, Darshan Dental College & Hospital, Udaipur, Rajasthan, India, Phone: +918690771870 e-mail: milapkaria@gmail.com

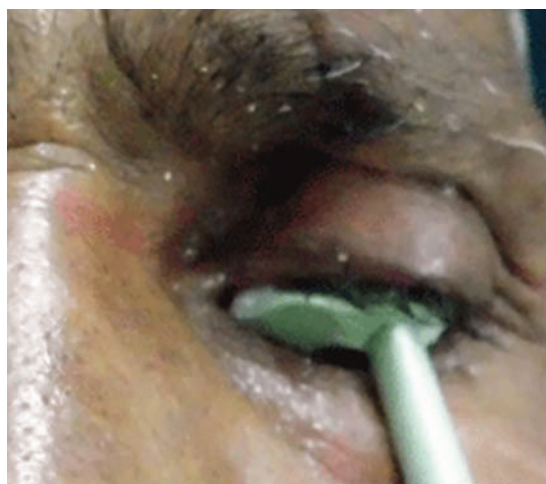

Fig. 2: Impression making with syringe tip

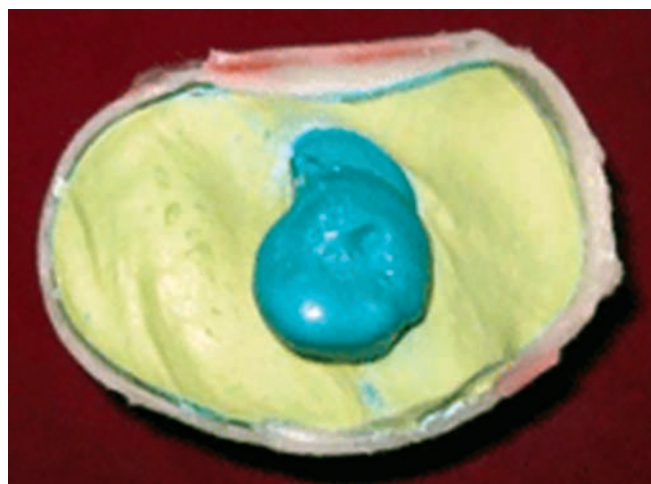

Fig. 3: Impression of the ocular defect

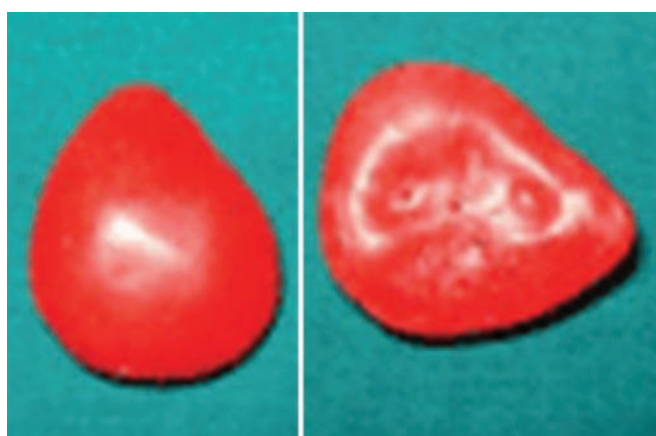

Fig. 4: Wax patterns

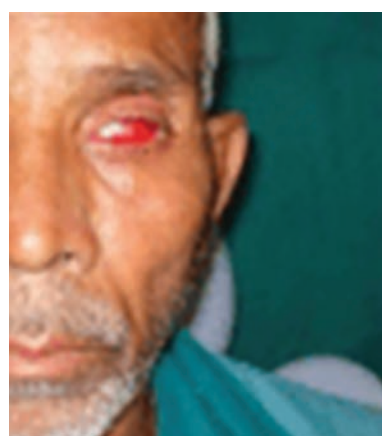

Fig. 5: Wax pattern try-in

and evaluated for fit, contour, esthetics, and comfort of the subject (Fig. 5). The iris plane and pupil point were evaluated by drawing guide lines on the patient's face. This was confirmed with the contralateral normal eye. The pattern was processed in heat-cured tooth-colored acrylic (DPI tooth molding powder, C shade). The scleral blank was then polished and tried in the subject's ocular defect. At try-in of the scleral blank, eye contour, and lid configurations was evaluated and approximated to that of the contralateral normal eye. Care was taken to see that the eyelid closed over the scleral blank normally like the contralateral normal eye.

The patient was asked to look straight at a distance, and a digital photo was made of the normal eye. The image was edited using Adobe Photoshop and a color print was obtained on photo paper. The iris portion of the photo was cut out and a layer of cyanoacrylate was applied to make it water resistant.

To obtain the convex shape of the cornea, self-cure clear acrylic was molded over the iris paper, polishing completed, and attached to the scleral blank at a pre-

determined position. The scleral blank was trimmed for 1 mm along the outer surface. Characterization of scleral portion was done with red color rayon thread attached by means of monomer polymer syrup. Yellow staining was also done along the scleral region. Final coat of heat-cure clear acrylic resin was packed on the surface of the characterized scleral blank and processed. Finishing and polishing of the prosthesis was done, and any residual sharp areas were avoided and trimmed (Fig. 6). The finished and polished eye prosthesis was inserted (Fig. 7).

## DISCUSSION

Several techniques have been used in fabricating and fitting artificial eyes. Empirically fitting a stock eye, modifying a stock eye by making an impression of the ocular defect, and the custom eye technique are the most commonly used techniques.<sup>6</sup> Disadvantages of stock eye prosthesis are numerous, starting from poor fit to infection of the tissue bed. In comparison, the custom-fabricated acrylic prosthesis is precise, has good fit, and

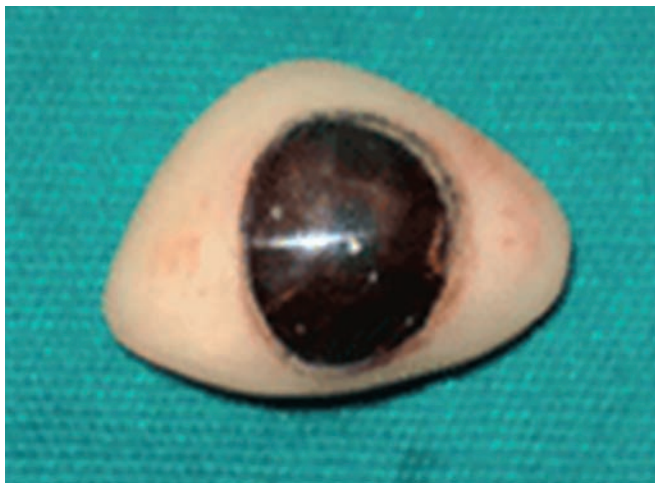

Fig. 6: Finished scleral blank



Fig. 7: Final prosthesis placed in ocular defect

is esthetically superior. This is so as an impression of the tissue bed of the patient is obtained prior to fabrication.<sup>6-9</sup> Direct impression was made of the tissue bed with addition silicone elastomeric impression material (Aquasil, Dentsply). This was a discourse from usual procedures of fabrication of custom tray to obtain the impression.<sup>1,2,4,6-9</sup> Traditionally, ocular prosthesis has incorporated the hand-painted iris into the prosthesis. Fernandes et al<sup>3</sup> had concluded in their study of 40 paint samples that all paints underwent alteration over time, with oil paint presenting the highest resistance to accelerated aging. However, digital reproduction of the iris is possible now with advanced photographic methods. Artopoulou et al<sup>6</sup> in their case report have discussed at length about the procedure for reproducing the patient's iris by digital photography. This procedure was adapted for the current case. Ocular button was not used to place the iris; instead, it was positioned directly on the scleral blank and secured with cyanoacrylate. This procedure conserves time, making the fabrication of the ocular prosthesis a day procedure.

## CONCLUSION

An alternative approach to fabrication of ocular prosthesis is presented in this case report. Direct impression with an elastomeric impression material (Aquasil, Dentsply) has been tried here with satisfactory results. Digital iris has

been incorporated in the ocular prosthesis instead of the hand-painted method. Both the techniques require further study to assess their efficacy and stability.

## REFERENCES

1. Jamayet NB, Srithavaj T, Alam MK. A complete procedure of ocular prosthesis: a case report. *Int Med J* 2013 Dec;20(6): 729-730.
2. Kaur A, Pavaiya A, Singh SV, Singh RD, Chand P. A simplified approach to fabrication of an ocular prosthesis: a case series. *Indian J Dent Res* 2010 Oct-Dec;21(4):615-617.
3. Fernandes AUR, Goiato MC, Batista MAJ, Santos DM. Color alteration of the paint used for iris painting in ocular prostheses. *Braz Oral Res* 2009 Oct-Dec;23(4):386-392.
4. Chiramana S, Anne G, Ravuri K, Boppana PP, Kumar S, Appana KC. A time saving method to fabricate a custom ocular prosthesis. *J Orofac Res* 2013 Jan-Mar;3(1):42-45.
5. The Academy of Prosthodontics. The glossary of prosthodontic terms. *J Prosthet Dent* 2005 Jul;94(1):10-92.
6. Artopoulou II, Montgomery PC, Wesley PJ, Lemon JC. Digital imaging in the fabrication of ocular prostheses. *J Prosthet Dent* 2006 Apr;95(4):327-330.
7. Kohli D, Mehta S, Makawana P, Choudhary S. An ocular prosthesis: a case report. *Pravara Med Rev* 2011 Dec;3(4):27.
8. Sinha ND, Bhandari AJ, Gangadhar SA. Fabrication of custom ocular prosthesis using a graph grid. *Pravara Med Rev* 2009 Mar;4(1):21-24.
9. Debnath N, Gupta R, Meenakshi A, Ramkumar K, John J. A simplified approach to fabricate a custom made ocular prosthesis. *Int J Prosthodont Restor Dent* 2013 Jan-Mar;3(1):25-29.